

## New technique of extra-abdominal intestinal anastomosis: Emergency life saving standard surgical procedure in many critical situations.

Dr. Faruquzzaman.

FCPS, MS, MRCS, MCPS Junior Consultant, Dept. of Surgery, Khulna Medical College Hospital, Bangladesh.



### Article History

Received : 25/03/2022

Accepted : 28/03/2022

Published : 29/03/2022

### Abstract:

Anastomosis leakage following intestinal anastomosis and the development of septic complications is a major problem for surgeons in certain clinical situations. There are many circumstances, where surgeons are in great trouble for decision making, where exteriorization of intestine or performing a primary anastomosis both is a risky procedure with a very fatal outcome. The purpose of this paper is to the introduction of a newer technique “extra-abdominal intestinal anastomosis”.

The ultimate aim of this research is to assess the outcome of this new procedure compatible with such situations with different important surgical aspects.

This prospective study was conducted with a total 42 patients of extra-abdominal small intestinal anastomosis done in Khulna Medical College Hospital (KMCH), Bangladesh. The study period was from January 2017 to November 2020. All the operations were done on emergency setup. Convenient purposive sampling was the sampling technique.

In this research, approximately 28.6% (12 patients) were undergone an emergency operation for the gangrenous intestine, followed by 19.0% (08 patients) for postoperative abdominal sepsis. Another important indication was strangulated hernia (07 patients, 11.9%). Extra-abdominal intestinal anastomosis on a trial basis was done in 42 patients in KMCH. Excellent results have been observed. Overall mortality and morbidity have been reduced. Moreover, due to less complications, hospital staying, the cost has been reduced, on the contrary, patients’ compliance has been increased. The mortality rate with extra-abdominal intestinal anastomosis was 14.3%, whereas it was reported to be very high previously in KMCH in many circumstances. Extra-intestinal leakage was observed in

approximately 26.2% of cases. Approximately in 14.3% patients of with extra-abdominal leakage, the extra-abdominal repair was possible without major consequences. Early internalization of the intestinal anastomosis with the closure of abdominal wall was possible on 7<sup>th</sup> to 14<sup>th</sup> postoperative day in approximately in 61.9% of patients with good results.

The newer method, extra-abdominal intestinal anastomosis is a resilient procedure in many emergency situations with fewer complications, less hospital staying, reduced mortality, morbidity rate, and excellent patient compliance.

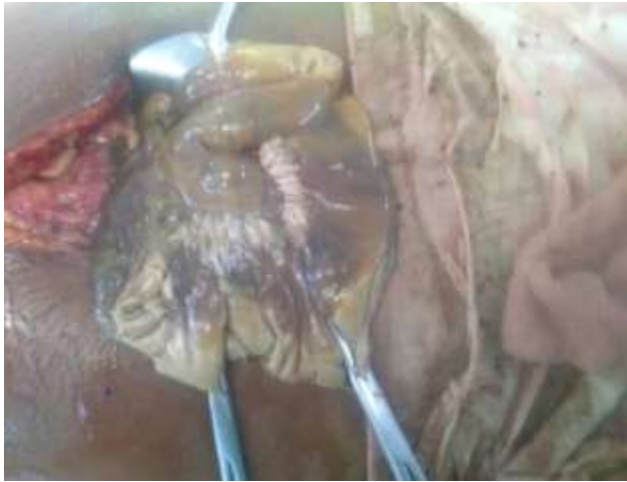**Keywords:** Extra-abdominal anastomosis, intestinal anastomosis, abdominal sepsis, mortality, morbidity.

### Introduction:

Anastomotic leakage remains a severe complication after abdominal surgery with considerable morbidity and mortality<sup>1-3</sup>. The frequency ranges from 1.8 to 19.2% and depends partly on different risk factors<sup>4-6</sup>. Anastomotic leak is one of the most fretted complications and its occurrence carries a significant degree of morbidity and mortality for affected patients<sup>7</sup>. **Anastomotic leaks** are defined as ‘**a leak of luminal contents from a surgical join**’. They are the most important complication to recognize following gastrointestinal surgery. **Early diagnosis, resuscitation, and treatment** of an anastomotic leak is key. Delay leads to prolonged contamination of the abdomen or chest by the luminal contents, leading to the development of severe sepsis and progression to

**multi-organ failure and death.** In many clinical circumstances (perforations, gangrene, traumatic injury, inadequate length of intestine, etc.), there is no alternative to perform jejuna or ileal anastomosis. In such cases, risk of anastomosis leakage and further complications, morbidity, and mortality are inevitable responses. In such cases, exteriorization of the bowel is not practically possible due to the problem of high output fistula. Therefore, it is a great challenge to salvage the patients in such a situation. For a very long time, this is a very practical challenge for the surgeons, where there is no good solution so far. However, the new technique of extra-abdominal anastomosis may be a problem-solving tool in such circumstances. The reported incidence varies from 6% to 30%<sup>8-10</sup>, largely based on the criteria for diagnosis and the length of follow-up, with an average of 11%<sup>4</sup>. The higher rate is seen in

lower anastomoses<sup>11-13</sup>. Anastomotic has been reported to increase the mortality rate from 1.6% to 12%<sup>14</sup>. Loop ileostomy closure is associated with a morbidity of 17.3% and mortality of 0.1-4%<sup>15-17</sup>.



**Figure I: Gross gangrene of jejunum-ileum due to superior mesentery artery thrombosis.**



**Figure II: Gross gangrene of jejunum-ileum due to superior mesentery artery thrombosis.**

There are so many clinical situations (figure I & II), where it is a great challenge for the surgeons to perform intestinal anastomosis or exteriorization of the intestine (problem of anastomosis leakage, short bowel syndrome, high output fistula, inadequate intestinal length, etc.). In such circumstances, extra-abdominal intestinal anastomosis is a possible solution. The main aim of this research is to describe the surgical technique and to assess the outcome and different aspects of the newly proposed method of “extra-abdominal intestinal anastomosis”.

#### **METHODS AND MATERIALS:**

This research was conducted as a prospective study with a total 42 patients of extra-abdominal small intestinal (jejuno-jejunal or jejuno-ileal or ileo-ileal) anastomosis in Khulna Medical College Hospital (KMCH), Bangladesh from January 2017 to November 2020. All the operations were done on an emergency basis with

gross peritoneal contamination. Convenient purposive sampling was used as a method of selecting samples on the basis of inclusion and exclusion criteria. The survey data were usually analyzed using both analytic as well as a descriptive statistics. Such as; mean, SD, percentage etc. Ethical clearance was taken individually from the patient and from the ethical review committee of Khulna Medical College Hospital.

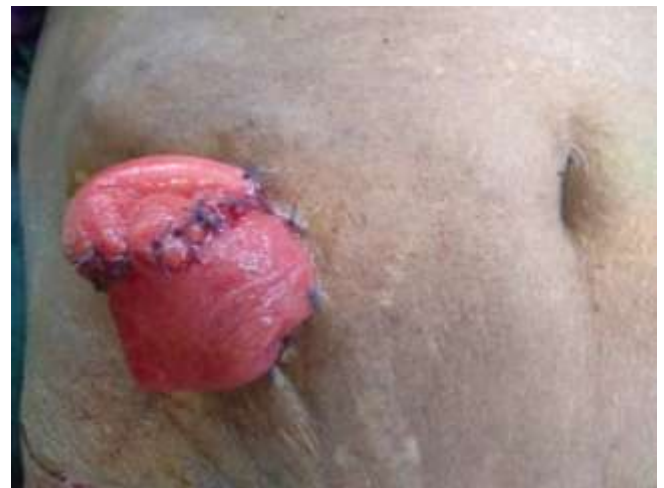#### **OPERATIONAL DEFINITION:**

##### **Extra-abdominal bowel anastomosis:**

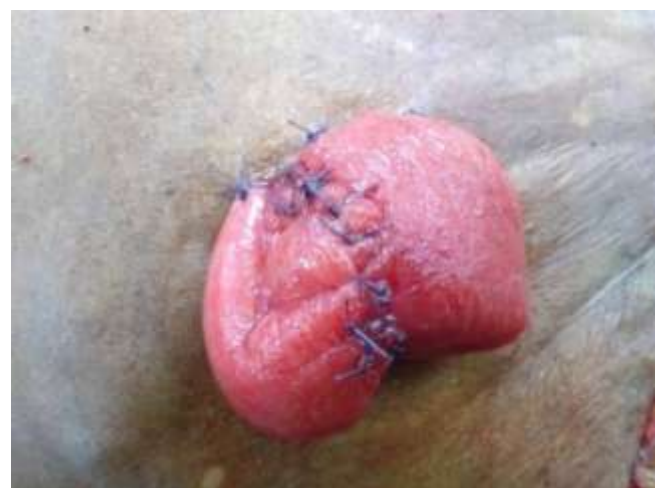Extra-abdominal bowel anastomosis is a surgical technique where the intestinal anastomosis is done outside the abdominal wall usually in a relatively sterile way.

##### **Operative procedure:**

Single-layer extra-mucosal or seromuscular anastomosis is done. Only skin fixation is done. Fascial layer fixation (fixation to fascia or peritoneum) is not done.



**Figure III: Extra-abdominal anastomosis.**



**Figure IV: Extra-abdominal anastomosis**

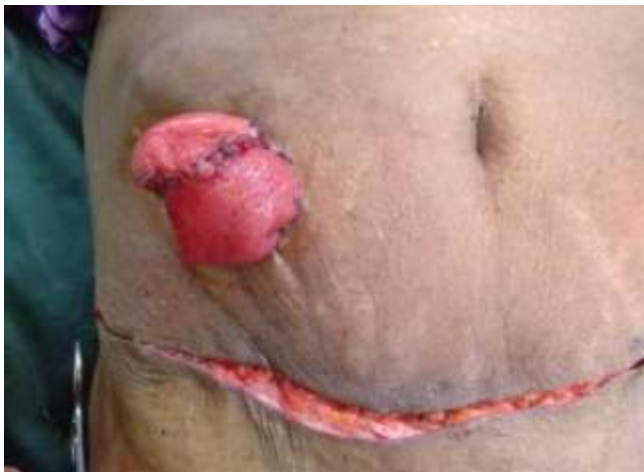

Figure V: Extra-abdominal anastomosis

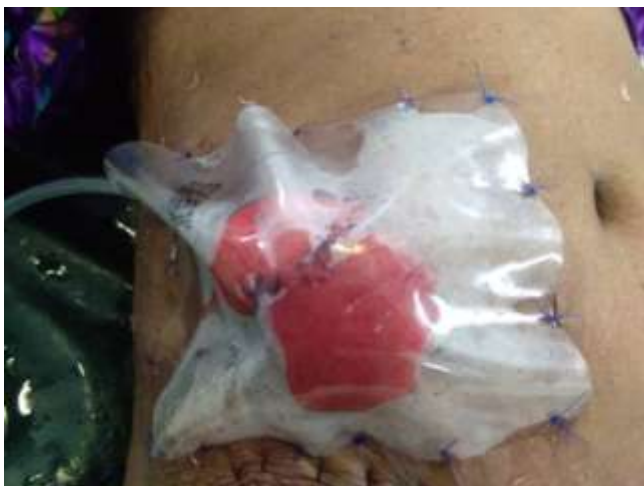

Figure VI: Sterile covering.

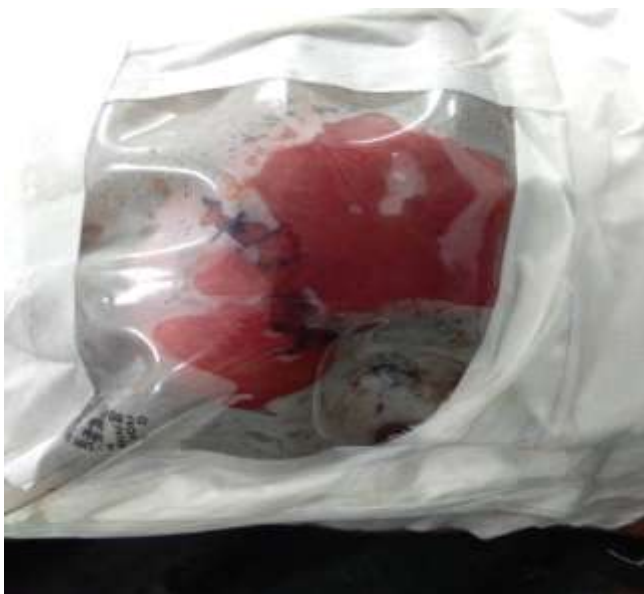

Figure VII: Sterile covering with sterile extra-abdominal drainage.

**Indication:**

**Absolute:**

- ✓ High risk anastomosis.
- ✓ Inadequate bowel length.

**Relative:**

- ✓ Vulnerable patient/surgery.
- ✓ Proximal anastomosis (jejunum with the chance of high output fistula) with gross peritoneal contamination with disease gut.
- ✓ Multiple bowel perforations (traumatic/pathological) with proximal extra-abdominal anastomosis with de-functioning of the rest of the perforated (repaired) gut.
- ✓ Other surgical considerations.

**Purpose/ advantage:**

- Good and effective surgical option and substitute of double-barrel ileostomy.
- Chance of anastomosis leakage and high output fistula is relatively very less.
- In case of inadequate gut length, immediate complications can be compensated.
- Complications of jejuna anastomosis leakage/ breakdown can be eliminated in many circumstances.
- In case of extra-abdominal anastomosis, if leakage occurs it can be gradually repaired extra-abdominally.
- In anastomosis leakage, the patient will be saved.
- Internalization of the bowel is relatively easier (maybe even done as day case procedure with local anesthesia). Major operation of ileostomy closure can be avoided.
- Early internalization of bowel is possible with high patient compliance.
- In case of leakage or indicated situation, conversion to double barrel ileostomy is possible.
- In case of double-barrel ileostomy, extra-abdominal anastomosis is possible in a risk-free way (distal patency and functional status can be also assessed).
- This is cost-effective and simpler technique, as the cost related to the application of ileostomy bag and respective care is not necessary with extra-abdominal anastomosis.

**Drawback:**

This new method is not compatible with all clinical scenarios, as the situations vary from person to person, pathology to pathology, factor to factor, etc. Therefore, the surgeon's consideration and concern are key factors here. Further trials on this new surgical technique are essential to justify the beneficiary effect and the limitation.

**Conversion:**

**Type 1:** Extra-abdominal anastomosis to double barrel ileostomy/jejunostomy/(colostomy).

**Type 2:** Double barrel ileostomy/jejunostomy/colostomy to the extra-abdominal anastomosis.

Age and sex distribution of all patients were shown in table1.

Age group (Years)	Male			Female		
	n	%	Mean±SD	n	%	Mean±SD
<30	02	4.8	54±2.1	00	00	55±2.0
30-39	02	4.8				
40-49	07	16.7				
50-60	14	33.3				
>60	05	11.9				
<b>Total</b>	<b>30</b>	<b>71.4</b>		<b>12</b>	<b>28.6</b>	

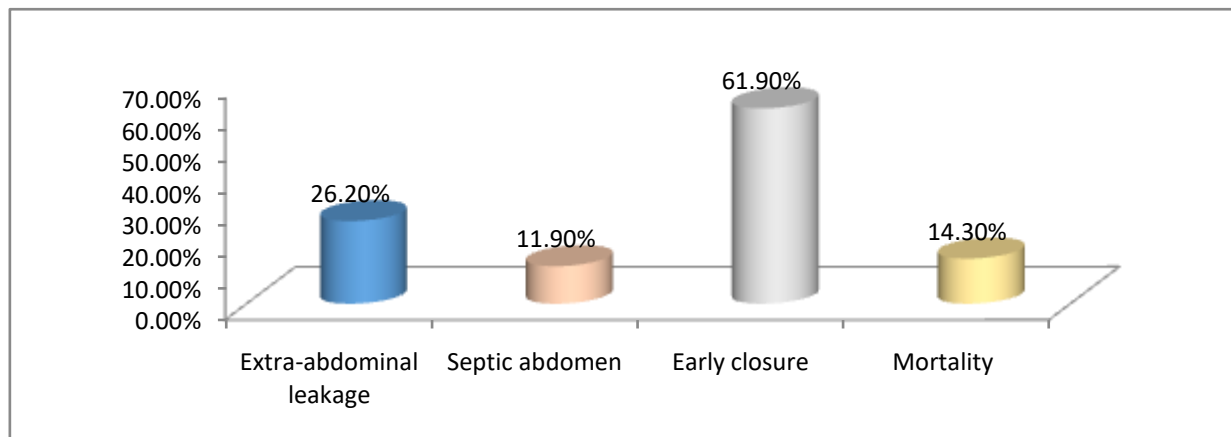
**Table 1: Age and sex distribution of study population.**

Pathology and indication for emergency operations were represented in table 2.

Indication	n	%
Inflammatory perforation	04	9.5
Traumatic perforation	03	7.1
Intestinal obstruction	03	7.1
Gross gangrene	12	28.6
Postoperative abdominal sepsis	08	19.0
Strangulated hernia	05	11.9
Others	07	16.7
<b>Total</b>	<b>42</b>	<b>100</b>

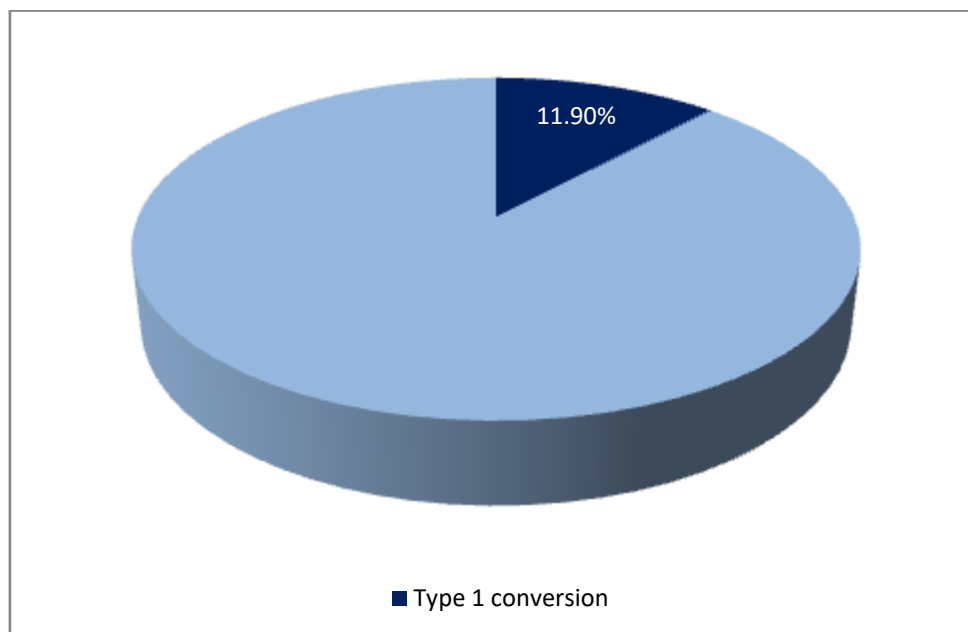
**Table 2: Indication of operation.**

Important major post-surgical events are depicted in figure 1.



**Figure 1: Major postoperative events.**

Most often, type 1 conversion of extra-abdominal anastomosis was not required. The overall rate of type 1 conversion is shown in figure 2



**Figure 2: Type 1 conversion rate.**

#### DISCUSSION:

In this research study, most of the patients were male (30 patients out of total 42 patients, 71.4%). Majority of the study population were in 50-60 years of age group, which were 33.3% and 16.7% respectively in both male and female (figure 1). Mean $\pm$ SD of age was 54 $\pm$ 2.1 and 55 $\pm$ 2.0 years in respective groups. In the research institute (Khulna Medical College Hospital, Bangladesh), it was a great challenge for the surgeon in many clinical scenarios (due to inadequate intestinal length, gross peritoneal contamination, gross intestinal gangrene, the chance of high anastomosis leakage, high output fistula, short bowel syndrome, etc.) for many years. Our experience reflects that in such situations, it is very difficult to salvage the patients from catastrophic outcomes even in short term. We were looking for a solution for a very long time to cope up the situation. We tried in different ways and techniques, but all failed. After many trials, we realized that extra-abdominal intestinal anastomosis is a possible solution in such relation.

In this research, most of the extra-abdominal anastomosis was done for gross intestinal gangrene (example-figure I & II). Approximately 28.6% (12 patients) were undergone emergency Laparotomy for gangrenous intestine (for superior mesenteric artery thrombosis and other causes), followed by 19.0% (08 patients) for postoperative abdominal sepsis (with history of previous hysterectomy, cesarean section, and other abdominal surgery). Strangulated hernia with gangrene was another important indication (07 patients, 11.9%). Other pathology like malignancy, perforated appendicitis with gross generalized peritonitis, inflammatory bowel diseases with sub-acute obstruction, etc. were also important indications (Table 2).

In Khulna Medical College Hospital, Bangladesh anastomosis leakage, development of abdominal sepsis, and the further

consequence was an inevitable outcome in many such clinical situations. However, with the introduction of extra-abdominal intestinal anastomosis on a trial basis, promising results have been observed (figure 1). Overall mortality and morbidity have been reduced. Moreover, due to less complications, hospital staying, cost has been reduced, on the contrary, patients' compliance have been increased. The results of this study suggest that the mortality rate with extra-abdominal intestinal anastomosis was 14.3% (06 out of total 42 patients). The incidence of extra-intestinal leakage was observed in approximately 26.2% (11) cases. And among this 11 patients, in 06 (14.3%) patients gradual extra-abdominal repair were possible without major leakage by simple stitching. Early internalization of the intestinal anastomosis with the closure of abdominal wall was possible on 7<sup>th</sup> to 14<sup>th</sup> postoperative day in approximately in 61.9% (26) patients with a good outcome. However type 1 conversion was required in 05 (11.9%) cases (figure 2). As in case of early closure, there is no necessity of closure of stomas later on and no need of stoma care and application of ileostomy bag and accessories, that is why, the overall hospital staying, cost and complications are significantly less. Therefore, this new method is not only cost effective, but also a reliable and resilient technique with excellent prognostic outcome, which has the potential to improve the overall mortality and morbidity.

#### LIMITATION:

In case of colostomy, this procedure was not done for this study.

#### RECOMMENDATION:

Further extended research is still required to justify the new life saving surgical procedure. Moreover, this trial was conducted with only jejunio-jejunal, jejunio-ileal and ileo-ileal anastomosis, more trials are required to assess the outcome with extra-abdominal

colonic anastomosis, as this has the potential to save too many lives in many critical circumstances.

#### CONCLUSION:

Extra-abdominal intestinal anastomosis (sterile) is a new, resilient and effective procedure especially in emergency setup to salvage patients. This technique is an association with fewer complications and less hospital staying. This is a cost-effective procedure with excellent patient's compliance. Moreover, this is an excellent problem-solving tool for surgeons in many critical scenarios.

#### CONFLICT OF INTEREST:

The author declares no conflict of interest.

## REFERENCES

1. Ashburn JH, Stocchi L, Kiran RP, et al. Consequences of anastomotic leak after restorative proctectomy for cancer: effect on long-term function and quality of life. *Dis Colon rectum*. 2013;56(3):275–280.
2. Di Cristofaro L, Ruffolo C, Pinto E, et al. Complications after surgery for colorectal cancer affect quality of life and surgeon-patient relationship. *Color Dis*. 2014;16(12):O407–O419. doi:10.1111/codi.12752.
3. Thornton M, Joshi H, Vimalachandran C, et al. Management and outcome of colorectal anastomotic leaks. *Int J Color Dis*. 2011;26(3):313–320.
4. Bakker IS, Grossmann I, Henneman D, et al. Risk factors for anastomotic leakage and leak-related mortality after colonic cancer surgery in a nationwide audit. *Br J Surg*. 2014;101(4):424–432.
5. Krarup PM, Jorgensen LN, Andreasen AH, et al. A nationwide study on anastomotic leakage after colonic cancer surgery. *Color Dis*. 2012;14(10):661–667.
6. Matthiessen P, Hallbook O, Rutegard J, et al. Defunctioning stoma reduces symptomatic anastomotic leakage after low anterior resection of the rectum for cancer: a randomized multicenter trial. *Ann Surg*. 2007;246(2):207–214.
7. Michael J. Stamos, Matthew T. Brady, Anastomotic leak: are we closer to eliminating its occurrence?, *Annals of Laparoscopic and Endoscopic Surgery*, *Ann Laparosc Endosc Surg* 2018;3:66
8. Isbister WH. Anastomotic leak in colorectal surgery: A single surgeon's experience. *ANZ J Surg* 2001;71:516-20.
9. Matthiessen P, Hallbook O, Andersson M, et al. Risk factors for anastomotic leakage after anterior resection of the rectum. *Colorectal Dis* 2004;6:462-9.
10. Paun BC, Cassie S, MacLean AR, et al. Postoperative complications following surgery for rectal cancer. *Ann Surg* 2010;251:807-18.
11. Park IJ. Influence of anastomotic leakage on oncological outcome in patients with rectal cancer. *J Gastrointest Surg* 2010;14:1190-6.
12. Park YA, Kim JM, Kim SA, et al. Totally robotic surgery for rectal cancer: from splenic flexure to pelvic floor in one setup. *Surg Endosc* 2010;24:715-20.
13. Snijders HS, Wouters MW, van Leersum NJ, et al. Meta-analysis of the risk for anastomotic leakage, the postoperative mortality caused by leakage in relation to the overall postoperative mortality. *Eur J Surg Oncol* 2012;38:1013-9.
14. Alves A, Panis Y, Trancart D, et al. Factors associated with clinically significant anastomotic leakage after large bowel resection: multivariate analysis of 707 patients. *World J Surg* 2002;26:499-502.
15. Wong KS, Remzi FH, Gorgun E, Arrigain S, Church JM, Preen M, Fazio VW. Loop ileostomy closure after restorative proctocolectomy: outcome in 1,504 patients. *Dis Colon Rectum*. 2005;48:243–250.
16. Chambers WM, Mortensen NJ. Postoperative leakage and abscess formation after colorectal surgery. *Best Pract Res Clin Gastroenterol*. 2004;18:865–880.
17. Chow A, Tilney HS, Paraskeva P, Jeyarajah S, Zacharakis E, Purkayastha S. The morbidity surrounding reversal of defunctioning ileostomies: a systematic review of 48 studies including 6,107 cases. *Int J Colorectal Dis*. 2009;24:711–723.